

Postoperative alopecia: A rare complication following total thyroidectomy and lateral neck dissection

Postoperative alopecia after thyroidectomy

Abdulkadir Çelik¹, Arslan Hasan Kocamaz², Ibrahim Uney³, Alper Varman⁴

¹Department of General Surgery, Dr. Ersin Arslan Training and Research Hospital, Gaziantep

²Department of General Surgery, Kayseri State Hospital, Kayseri

³Department of General Surgery, Faculty of Medicine, Kutahya Health Sciences University, Kütahya

⁴Department of General Surgery, School of Medicine, Necmettin Erbakan University, Konya, Turkey

Abstract

Postoperative alopecia is an uncommon complication following total thyroidectomy and lateral neck dissection, typically used to treat thyroid cancer. This case study details a 25-year-old male who, after undergoing these procedures, developed alopecia in the occipital region. The patient had a history of papillary thyroid carcinoma and underwent surgery to address cancerous nodules and lymph nodes. Post-surgery, he experienced serous discharge from the occipital scalp, and by the 20th postoperative day, localized alopecia was noted.

Possible causes of this rare complication include pressure on the scalp during surgery, ischemia of subcutaneous tissues, or the effects of antiseptic agents used in the procedure. The prolonged surgical duration and patient positioning may also contribute. Proper positioning and cautious use of antiseptics are crucial in preventing such issues. While treatment initially involved topical steroids and local care, similar cases often resolve with appropriate management, though there remains a risk of permanent alopecia.

This case underscores the need for vigilance in patient positioning and postoperative care to prevent rare complications. Multidisciplinary collaboration can enhance the management of such conditions, emphasizing the importance of early diagnosis and intervention.

Keywords

Alopecia, Thyroidectomy, Thyroid Cancer

DOI:10.4328/ECAM.10104

Received : 2024-09-27

Accepted : 2024-10-16

Published Online : 2024-10-17

Printed Online : 2024-10-20

Eu Clin Anal Med 2024;12(Suppl 1):S23-25

Corresponding Author: Arslan Hasan Kocamaz, Department of General Surgery, Kayseri State Hospital, Kayseri, Turkey.

E-Mail: md.ahkocamaz@gmail.com · **P:** +90 530 967 64 11 · **Corresponding Author ORCID ID:** <https://orcid.org/0000-0002-5257-9611>

Other Authors ORCID ID: Abdulkadir Çelik, <https://orcid.org/0000-0002-5537-7791> · Ibrahim Uney, <https://orcid.org/0000-0002-5235-8421>

Alper Varman, <https://orcid.org/0000-0002-1918-5143>

How to cite this article: Abdulkadir Çelik, Arslan Hasan Kocamaz, Ibrahim Uney, Alper Varman. Postoperative alopecia: A rare complication following total thyroidectomy and lateral neck dissection. Eu Clin Anal Med 2024;12(Suppl 1):S23-25

Introduction

Total thyroidectomy and bilateral lateral neck dissection are common surgical procedures used to treat thyroid cancer. Although these surgeries generally have high success rates, certain postoperative complications can arise, including hypoparathyroidism, recurrent laryngeal nerve injury, and hematoma [1,2]. However, alopecia, as a rare complication, is less frequently reported in the literature [3,4]. Post-surgical alopecia is often attributed to factors such as pressure applied to subcutaneous tissues or the toxic effects of antiseptic agents used during surgery [5,6]. This case report presents a patient who developed alopecia in the occipital region following total thyroidectomy. The potential mechanisms behind this rare complication and its clinical significance will be discussed.

Case Report

A 25-year-old male patient presented with complaints of swelling in the neck. Physical examination revealed a palpable nodule approximately 2 cm in diameter in the left lobe of the thyroid gland and a palpable mass about 4-5 cm in the left jugular chain. The patient's family history was notable for papillary thyroid cancer in his mother and aunt, both of whom had undergone surgery. Laboratory tests showed that the patient was euthyroid. Neck ultrasonography (USG) showed a 2x1 cm nodule that looked suspicious in the left lobe and lymphadenopathy that looked like cancer in level 3 of the left neck. Numerous lymphadenopathies were also observed in the central regions on both sides. A fine needle aspiration biopsy (FNAB) of the thyroid nodule confirmed papillary thyroid carcinoma. The level 3 lymph node on the left side showed metastatic carcinoma, according to FNAB.

The patient underwent total thyroidectomy, bilateral central lymph node dissection, and left lateral lymph node dissection (Figure 1). The operation lasted 95 minutes, during which the patient's occipital region was supported and maintained in a cervical hyperextension position. The patient was discharged on the third postoperative day in good health.

Histopathological examination of the thyroid tissue revealed a 2x1.8 cm classic subtype of papillary thyroid carcinoma. Of the 53 lymph nodes excised from the central and lateral regions, 25 were found to be metastatic.

On the first postoperative day, serous discharge from the patient's occipital scalp was observed. Since no pathology was expected in this area, dry dressing was applied. On the 20th postoperative day, the patient returned for a follow-up visit, during which localized alopecia in the occipital region was noted (Figure 2).

The patient was referred to dermatology, and topical steroid treatment was initiated. We considered this condition a rare postoperative complication and discussed the potential causes of alopecia.

Ethical approval

This study was approved by the Ethics Committee of Necmettin Erbakan University for Non-Drug and Non-Medical Device Research. (Date: 2024-10-04, No:2024/5238).

Discussion

Papillary thyroid carcinoma (PTC) accounts for 80% of all thyroid malignancies [7]. Therefore, it is commonly observed, and in some cases, lateral neck dissection is required. This case highlights a rare complication of postoperative alopecia following total thyroidectomy and lateral neck dissection due to papillary thyroid carcinoma. The condition may be caused by pressure exerted on the scalp during surgery, subcutaneous tissue ischemia, or the toxic effects of antiseptic agents used during the procedure [3,6,8]. Similar cases have

been linked to prolonged surgical duration and inadequate patient positioning, both of which may contribute to the development of this complication [4].

Proper patient positioning during surgery is crucial in preventing such complications [9]. In this case, serous discharge from the occipital region and subsequent alopecia suggest potential damage to the subcutaneous tissues in this area. Special attention should be given to the positioning of the patient's head during head and neck surgeries, avoiding prolonged pressure on specific points. Additionally, the potential toxic effects of antiseptic agents on the skin should be considered, and their use should be carefully managed [1].

Povidone-iodine and similar antiseptic agents are known to cause toxic reactions, particularly in sensitive skin areas [6]. This must be considered when dealing with postoperative alopecia. Reports in the literature describe skin reactions following prolonged exposure to such agents. Therefore, careful selection and application of antiseptic agents in postoperative care are essential.

The treatment and management of alopecia should address the underlying cause. In this case, local care and antiseptic dressings were applied as initial treatments. However, similar cases reported in the literature indicate that surgery-related alopecia is generally temporary and resolves with appropriate care over time [3]. Despite this, there is a risk of permanent alopecia, underscoring the importance of early intervention and long-term follow-up [4].

This case emphasizes the need for awareness of rare complications that can occur during and after thyroid surgery. Surgeons must be vigilant about protecting the surgical field, ensuring proper patient positioning, and conducting thorough postoperative follow-ups [1,9]. A multidisciplinary approach involving dermatology, endocrinology, and

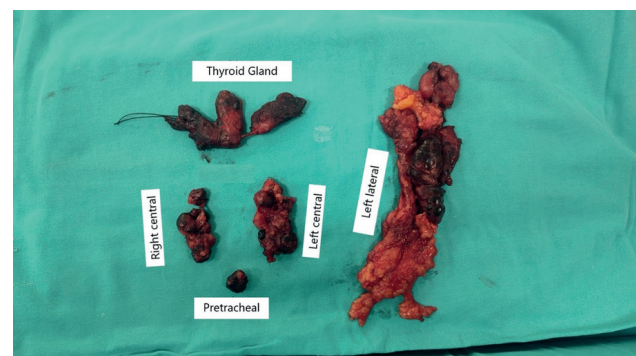


Figure 1. Total thyroidectomy and lymph node dissection post-operative piece

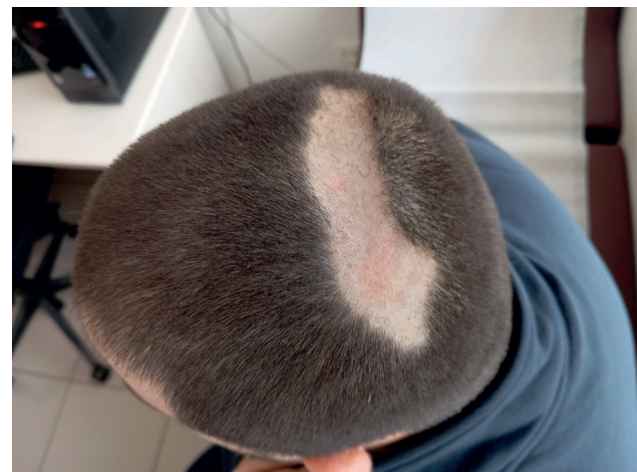

Figure 2. Alopecia following total thyroidectomy and lymph node dissection

surgery teams may lead to more effective management of such rare complications [2].

Conclusion

This case underlines the importance of recognizing postoperative alopecia as a rare complication following total thyroidectomy and bilateral lateral neck dissection. Surgeons should be aware of the need for correct patient positioning during surgery and diligent postoperative monitoring. Early diagnosis and appropriate treatment are critical for managing such complications. This case aims to raise awareness of rare surgical complications and highlights the value of a multidisciplinary approach in addressing these situations.

Scientific Responsibility Statement

The authors declare that they are responsible for the article's scientific content including study design, data collection, analysis and interpretation, writing, some of the main line, or all of the preparation and scientific review of the contents and approval of the final version of the article.

Animal and Human Rights Statement

All procedures performed in this study were in accordance with the ethical standards of the institutional and/or national research committee and with the 1964 Helsinki Declaration and its later amendments or comparable ethical standards.

Conflict of Interest

The authors declare that there is no conflict of interest.

References

1. Boyer JD, Vidmar DA. Postoperative alopecia: A case report and literature review. *Cutis*. 1994;54(5):321-2.
2. Al-Fakhri N, Schwartz A, Runkel N, Buhr HJ. Rate of complications with systematic exposure of the recurrent laryngeal nerve and parathyroid glands in operations for benign thyroid gland diseases. *Zentralblatt für Chirurgie*. 1998;123(1):21-24.
3. Cernea CR, Brandão LG, Hojaij FC. How to minimize complications in thyroid surgery?. *Auris Nasus Larynx*. 2010;37(1):1-5.
4. Chang ZY, Ngian J, Chong C, Chong CT. Postoperative permanent pressure alopecia. *J Anesth*. 2016;30(2):349-51.
5. Rosato L, Avenia N, Bernante P, De Palma M, Gulino G, Nasi PG, et al. Complications of thyroid surgery: Analysis of a multicentric study on 14,934 patients operated on in Italy over 5 years. *World J Surg*. 2004;28(3):271-6.
6. Christou N, Mathonnet M. Complications after total thyroidectomy. *J Visceral Surg*. 2013;150(4):249-56.
7. Alkan S, Aksoy F, Kocamaz AH, Senturk M, Varman A, Findik S, et al. Correlation between BRAFV600E positivity and recurrence and poor prognosis in preoperative fine needle aspiration biopsy of papillary thyroid carcinoma. *Selcuk Med J*. 2024;40(2):57-62.
8. Grogan RH, Mitmaker EJ, Hwang J, Gosnell JE, Duh QY, Clark OH, et al. A population-based prospective cohort study of complications after thyroidectomy in the elderly. *J Clin Endocrinol Metab*. 2012;97(5):1645-53.
9. Fewins J, Simpson CB, Miller FR. Complications of thyroid and parathyroid surgery. *Otolaryngol Clin North Am*. 2003;36(1):189-x.